

RESEARCH ARTICLE

Evaluation of hepatoprotective activity of aqueous extract of *Phyllanthus fraternus* in Wistar rats

Naveen Alasyam¹, Naveen Pokala², Premendran John³

¹Department of Pharmacology, Vishnu Dental College, Bhimavaram, Andhra Pradesh, India, ²Department of Pharmacology, Mamata Medical College, Khammam, Telangana, India, ³Department of Pharmacology, Mamata Medical College, Khammam, Telangana, India

Correspondence to: Naveen Pokala, E-mail: naveenpokala@yahoo.com

Received: December 18, 2018; Accepted: January 12, 2019

ABSTRACT

Background: We hypothesized that carbon tetrachloride-induced hepatotoxicity may be prevented by oral administration of *Phyllanthus fraternus* extract by inhibiting lipid peroxidation. **Aims and Objectives:** The present study was undertaken to evaluate the hepatoprotective activity of the aqueous extract of *P. fraternus* (AEPF) in Wistar rats. **Materials and Methods:** Five groups of Wistar rats were selected from 30 healthy animals, with six rats in each group. Group A received normal saline 10 ml/kg (p.o). Group B animals were fed with normal saline (10 ml/kg, p.o.). Group C animals were treated with Liv 52–100 mg/kg orally. Groups D and E rats were treated with plant extract orally once daily at the dosage of 250 and 500 mg/kg, respectively. Total duration of experiment is 20 days; CCl₄: Olive oil was given i.p on 2nd, 5th, and 8th days for all group of rats except Group A. On the 21st day, biochemical parameters such as serum glutamic oxaloacetic transaminase (SGOT), serum glutamic pyruvic transaminase (SGPT), alkaline phosphatase (ALP), bilirubin, cholesterol, and total protein were estimated from the collected blood. Liver tissues were collected from rats for histopathological examination. **Results:** *P. fraternus* exhibited judicious defensive effect by lowering (serum levels of SGOT, SGPT, ALP, bilirubin, and cholesterol) and rising total protein levels. The reduction of necrosis and sinusoids was observed in histopathological examination. **Conclusion:** The present study results support that the AEPF have a dose-dependent hepatoprotective activity.

KEY WORDS: Carbon Tetrachloride; Hepatoprotective Activity; *Phyllanthus fraternus*; Biochemical Parameters; Necrosis

INTRODUCTION

Plants were used during the age for cure and treatment of diseases since the start of mankind. Phytotherapy is the isolation of pure phytochemicals from the plant and plant extract to cure the diseases. Plants have been used to treat the many diseases such as liver diseases, heart problems, lead and mercury intoxication, and scarlet fever.^[1] Only 1–2% of the global plants have been

reasonably well investigated out of 250,000–500, 000 species of plants. Even today, the synthetic drugs are superior in their number than the natural ones, but still many synthetic drugs have been derived from plants and animals.^[2]

The liver is the main organ for biotransformation and elimination. It is always capable with the task of detoxification of xenobiotics, environmental pollutants, and chemotherapeutic agents.^[3] CCl₄, paracetamol, D-galactosamine, alcohol, rifampicin, and thioacetamide produce hepatotoxicity through different mechanisms.^[4] Therefore, these drugs are called hepatotoxic agents.

Phyllanthus fraternus belongs to *Euphorbiaceae*^[5] family. It is frequently called as “Bhumyamlaki” (Nela vusiri). Various biological activities of this plant are hepatoprotective

Access this article online

Website: www.njppp.com

Quick Response code

DOI: 10.5455/njppp.2019.9.1237012012019



National Journal of Physiology, Pharmacy and Pharmacology Online 2019. © 2019 Naveen Pokala, et al. This is an Open Access article distributed under the terms of the Creative Commons Attribution 4.0 International License (<http://creativecommons.org/licenses/by/4.0/>), allowing third parties to copy and redistribute the material in any medium or format and to remix, transform, and build upon the material for any purpose, even commercially, provided the original work is properly cited and states its license.

activity, anti-inflammatory activity, antinociceptive activity, antioxidant activity, antimicrobial activity, antifertility activity, antidiabetic activity, antiviral activity, antidote to snake bite, and wound healing activity.^[6,7] These properties are speculated to the existence of phyllanthin, hypophyllanthin, nirphyllin, phyllinirurin, phyllanthol, phyllanthenol, rhamnopyranoside, phyllanthenone, lintetralin, astragalol, cymene, niranthin, nirtetralin, nirurisode, phyllochrysin, and 4-methoxy-securinine.^[8] Very based on the above medicinal properties, the present study was aimed to examine the hepatoprotective activity of the aqueous extract of *P. fraternus* (AEPF) against CCl₄-induced hepatic damage in rats.

MATERIALS AND METHODS

Study Design

This was a research article.

Study setting

The present study was conducted at the Department of Pharmacology, Mamata Medical College, Khammam, Telangana, India.

Animals

Five groups of Wistar rats were selected from 30 healthy animals, with six rats in each group. Both male and female, weighing around 200 g, were preferred for the study. All animals were maintained at 27–29°C. 18 h before the experiment, food was limited to all animals, but free access to water was allowed. All the animals were hydrated orally with 10 ml/kg of 0.9% normal saline for 7 days.

- Group A ($n = 6$): Normal control (normal saline was administered orally daily for 20 days).
- Group B ($n = 6$): CCL₄ control (normal saline and CCL₄).
- Group C ($n = 6$): Standard group (Liv-52 100 mg/kg (p.o) daily for 20 days).
- Group D ($n = 6$): Test Group-I (*P. fraternus* extract 250 mg/kg (p.o) daily for 20 days).
- Group E ($n = 6$): Test Group-II (*P. fraternus* extract 500 mg/kg (p.o) daily for 20 days).

CCl₄: Olive oil was given intraperitoneally on 2nd, 5th, and 8th days for all group of rats except Group A (normal control) and Group C.

Chemicals

Carbon tetrachloride (Molychem) and Tab. Liv 52 (The Himalaya Drug Company) were used in the study.

Extraction Procedure

P. fraternus leaves were collected from local places near Khammam city and were authenticated by Professor in

the Department of Pharmacology, S.V. Ayurvedic College, Tirupati. Extract was prepared using the Soxhlet extraction.^[9] *Phyllanthus* leaves were shade dried at a room temperature for almost 1 week. These plant leaves were crushed in the form of fined powder using a mixer grinder. This fine leaf powder was then weighed and used for extraction using distilled water as a solvent. The solvent is evaporated then at the room temperature to get a reddish brownish-colored extract. This obtained extract was stored at a temperature of 2–8°C until further any other use.

Estimation of Biochemical Parameters

On the 21st day, mild ether was used for anesthetization of animals and cardiac puncture method was used for collection of blood samples. The samples were centrifuged and plasma was separated. Biochemical parameters such as liver functional test, cholesterol, and total proteins were measured using standard methods.^[10]

Histopathology

Livers were isolated from the experimental animals, and they were used for histopathological examination.^[11]

Ethical considerations

Experimental protocol was approved by the Institutional Animal Ethics Committee of Mamata Medical College.

Statistical Analysis

Data were analyzed using SPSS 20.0 version. One-way ANOVA followed by Tukey's test was applied to observe the significance of difference between the groups. $P < 0.05$ was considered as statistically significant.

RESULTS

Group B is treated with toxic doses of carbon tetrachloride which had significantly elevated the values of the liver functional test, cholesterol and total proteins levels were reduced when compared to Group A. When treated with hepatotoxic dose of carbon tetrachloride followed by Liv-52 and different doses of *P. fraternus* (250 and 500 mg/kg po). It showed that significantly lowered values of the liver functional test, cholesterol, bilirubin direct, bilirubin total, and total protein levels were significantly increased ($P < 0.05$) when compared to CCl₄ control group (Group B). As shown in Bardigram [Figures 1 and 2].

The histopathological examination of Group A livers showed a normal arrangement of the hepatocytes, with clearly visible nuclei, central vein, and portal triad [Figure 3]. In Group B of all rats, hepatocytes show steatosis and cytoplasmic vacuolations with ballooning degeneration, and the midzonal

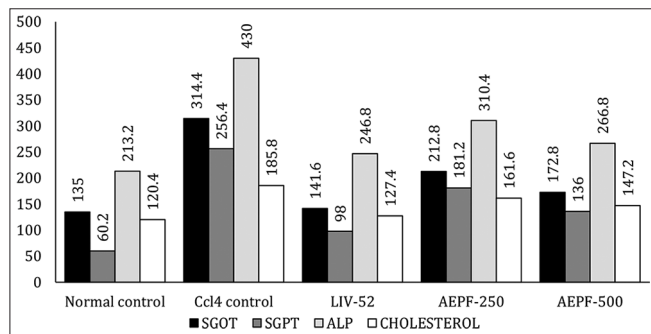


Figure 1: Effect of *Phyllanthus fraternus* on serum glutamic oxaloacetic transaminase, serum glutamic pyruvic transaminase, alkaline phosphatase, and cholesterol in CCl₄-induced hepatotoxicity in Wistar rats

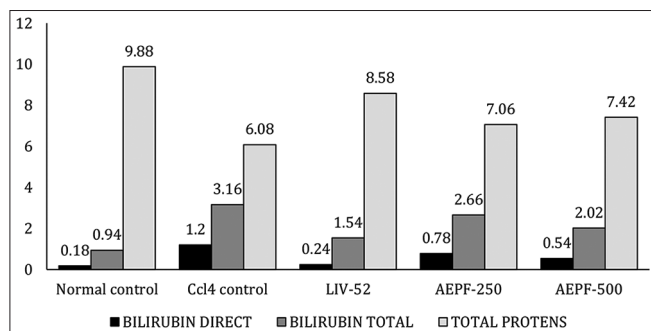


Figure 2: Effect of *Phyllanthus fraternus* on serum bilirubin and total proteins in CCl₄-induced hepatotoxicity in Wistar rats. AEPF: Aqueous extract of *P. fraternus*

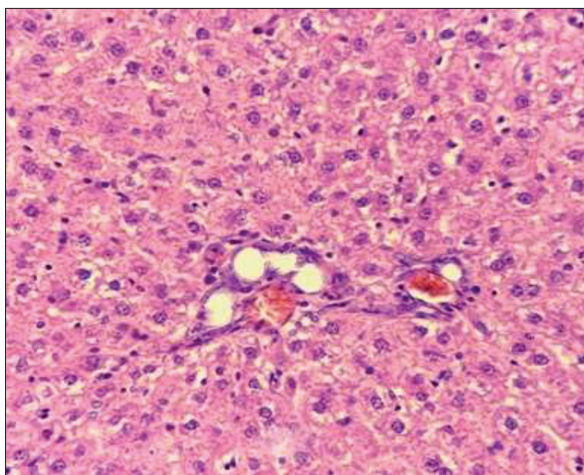


Figure 3: Histopathology of normal control (normal saline)

region shows inflammatory infiltration and congestion of central vein [Figure 4]. In Groups C, D, and E, there was a marked reduction in sinusoidal congestion, cloudy swelling, and fatty change. The central veins and sinusoids appeared unremarkable (Figures 5-7).

DISCUSSION

The study was aimed to explore the hepatoprotective activity of the AEPF in Wistar rats. Carbon tetrachloride-induced

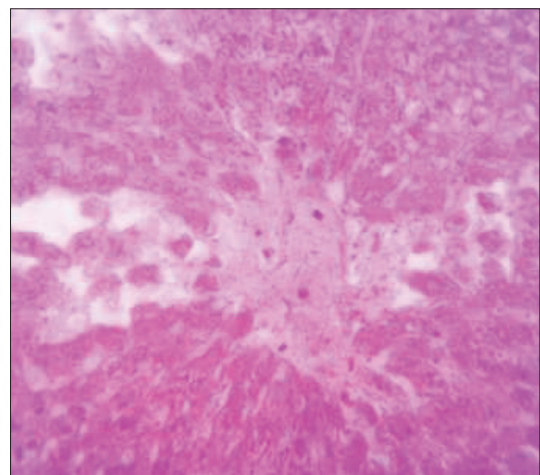


Figure 4: Histopathology of CCL4 control (CCL4)

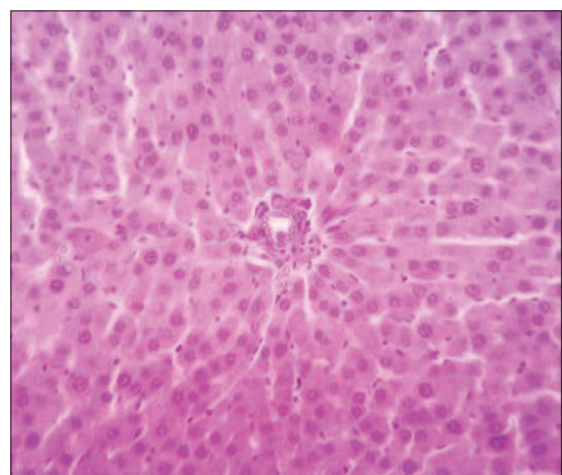


Figure 5: Histopathology of standard (Liv. 52)

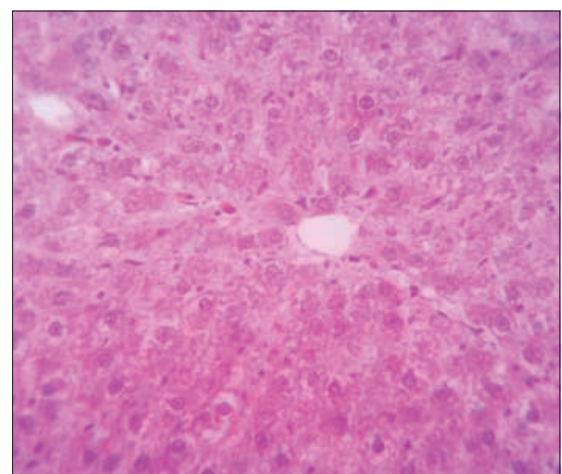


Figure 6: Histopathology of *Phyllanthus fraternus* - 250 mg/kg

hepatic injury was used for the present study. It was most acceptable method for hepatoprotective activity of plant extracts.^[12] We agree with the previous studies as we have observed in present study significantly reduce the values of the serum glutamic oxaloacetic transaminase, serum glutamic pyruvic transaminase, alkaline phosphatase (ALP),

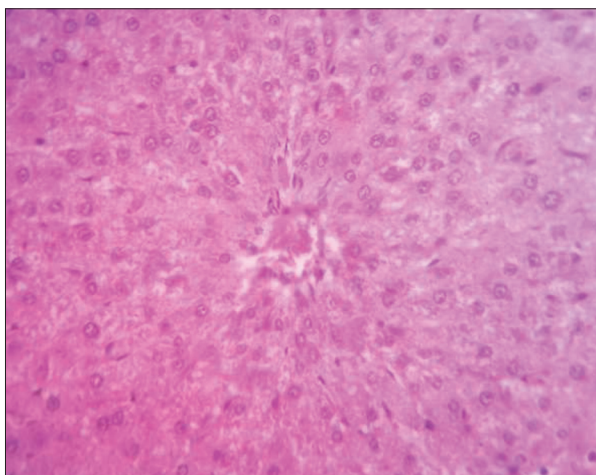


Figure 7: Histopathology of *Phyllanthus fraternus* - 500 mg/kg

cholesterol, bilirubin direct and bilirubin total and a significant increase in total protein levels in Group D and Group E when compared to CCl₄ control group (Group B).^[8,9] Which is an indication of repair of hepatic tissue and stabilization plasma membrane by plant extract.^[13] ALP is an enzyme and it reflects the pathological amendment in biliary flow.^[14] Increased ALP and bilirubin levels were significantly reduced in Groups D and E; it suggests the possibility of the test drug being able to stabilize biliary dysfunction in rat liver during hepatic injury. In this study, the protein level was reduced in Group B because CCl₄ changes the structure of endoplasmic reticulum which leads to reduction in protein synthesis. This might be due to carbon tetrachloride metabolized into trichloromethyl free radical (CCl₃) in endoplasmic reticulum, and it is a free radical, which combined with cellular lipids and proteins in the presence of oxygen to induce lipid peroxidation.^[15-17] In Groups D and E, marked elevation of total protein levels was observed. Hence, it is evident that plant extracts can restore the normal values of total proteins by increasing the synthesis.^[18] Our results support earlier studies as we have observed that *P. fraternus* provided significant protection against the toxic effect of CCl₄ on the liver. Histological studies reveal the changes, which take place during the damage and recovery. The extract mediated recovery supports the hepatoprotective activity of the same.

CONCLUSION

The study results support that the *P. fraternus* has dose-dependent hepatoprotective activity. The study highlights the need of further detailed studies to recommend the implementation of AEPF in the management of liver diseases in general.

ACKNOWLEDGMENT

Our sincere thanks to Dr. G Sai Sailesh Kumar, Assistant Professor and Head of the Department (I/C), Department of Physiology, Vishnu Dental College, for his support and valuable suggestions.

REFERENCES

1. Said HM. Medicinal Herbal-a Textbook for Medical Students and Doctors. Vol. 1. Pakistan: Hamdard Foundation; 1996. p. 294.
2. Alasyam N, Narapogu V, John P, Ubedulla S, Pokala N. Hepatoprotective activity of aqueous extract of *Andrographis paniculata*. Int J Pharmacol Clin Sci 2016;5:113-7.
3. Singh S, Mehta A, Mehta P. Hepatoprotective activity of *Cajanus cajan* against carbon tetrachloride induced liver damage. Int J Pharm Pharm Sci 2011;3:146-7.
4. Gond NY, Khadabadi SS. Hepatoprotective activity of *Ficus carica* leaf extract on rifampicin-induced hepatic damage in rats. Indian J Pharm Sci 2008;70:364-6.
5. Mehta K, Patel BN, Jain BK. Antimicrobial activity of root extract of *Phyllanthus fraternus* Webster: An ethnomedicinal plant. Res J Recent Sci 2014;3:275-8.
6. Sarin B, Verma N, Martin JP, Mohanty A. An overview of important ethnomedicinal herbs of *Phyllanthus* species: Present status and future prospects. ScientificWorldJournal 2014;2014:839172.
7. Singh SK, Prakash V. Toxicity assessment of *Oxalis corniculata* and *Phyllanthus fraternus* plants. Int J Pharm Pharm Sci 2014;6:388-92.
8. Bhattacharjee R, Sil PC. Protein isolate from the herb, *Phyllanthus niruri* L. (Euphorbiaceae), plays hepatoprotective role against carbon tetrachloride induced liver damage via its antioxidant properties. Food Chem Toxicol 2007;45:817-26.
9. Mehta RS, Shankar MB, Geetha M, Saluja AK. Hepatoprotective activity of *Trianthema portulacastrum*. Indian Drugs 1999;36:241-4.
10. Gupta RK, Kesari AN, Watal G, Murthy PS, Chandra R, Tandon V, et al. Nutritional and hypoglycemic effect of fruit pulp of *Annona squamosa* in normal healthy and alloxan-induced diabetic rabbits. Ann Nutr Metab 2005;49:407-13.
11. Galighor AE, Kozloff EN. Essentials of Practical Microtechnique. 2nd ed. New York: Lea and Febiger; 1976.
12. Kiso Y, Tohkin M, Hikino H. Assay method for antihepatotoxic activity using carbon tetrachloride induced cytotoxicity in primary cultured hepatocytes. Planta Med 1983;49:222-5.
13. Thabrew MI, Joice PD, Rajatissa W. A comparative study of the efficacy of *Pavetta indica* and *Osbeckia octandra* in the treatment of liver dysfunction. Planta Med 1987;53:239-41.
14. Ploa GL, Hewitt WR. Principle and Methods of Toxicology. 2nd ed. New York: Raven Press; 1989. p. 399.
15. Madhavan V, Murali A, Yoganarsimhan S, Pandey AS. Protective effect of the roots of *Capparis sepiaria* Linn. (Himsra) on carbon tetrachloride-induced hepatotoxicity. Asian J Tradit Med 2012;7:18-28.
16. Krishna BK, Mruthunjaya K, Patel JA. Antioxidant and hepatoprotective activity of leaf extract of *Justica gendrerussa*. Int J Biol Chem 2009;3:99-110.
17. Kaplowitz N, Aw TY, Simon FR, Stolz A. Drug-induced hepatotoxicity. Ann Intern Med 1986;104:826-39.
18. Firdous SM, Raju K, Pallab H. Evaluation of hepatoprotective activity of saponin of *Momordica dioica* Roxb. Against CCl₄ induced hepatic injury in rats. Pharmacol Online 2008;3:487-94.

How to cite this article: Alasyam N, Pokala N, John P. Evaluation of hepatoprotective activity of aqueous extract of *Phyllanthus fraternus* in Wistar rats. Natl J Physiol Pharm Pharmacol 2019;9(3):239-242.

Source of Support: Nil, **Conflict of Interest:** None declared.